Vertebral Column

Dr. Zaid Jafar Albachachy
Orthopedic & Trauma surgeon
M.B.Ch.B – CABMS.(orth.)
1st Nov. 2022

Introduction

- The vertebral column (spine), extending from the cranium (skull) to the apex of the coccyx, forms the skeleton of the neck and back and is the main part of the axial skeleton (articulated bones of the cranium, vertebral column, ribs, and sternum).
- ***The vertebral column function***:

1. protects the spinal cord and spinal nerves,
2. supports the weight of the body superior to the level of the pelvis,
3. provides a partly rigid and flexible axis for the body and
4. a pivot for the head, and plays an important role in posture and locomotion.

- The adult vertebral column typically consists of ***33 vertebrae*** arranged in five regions: ***7 cervical***, ***12 thoracic***, ***5 lumbar***, ***5 sacral***, and ***4 coccygeal.***

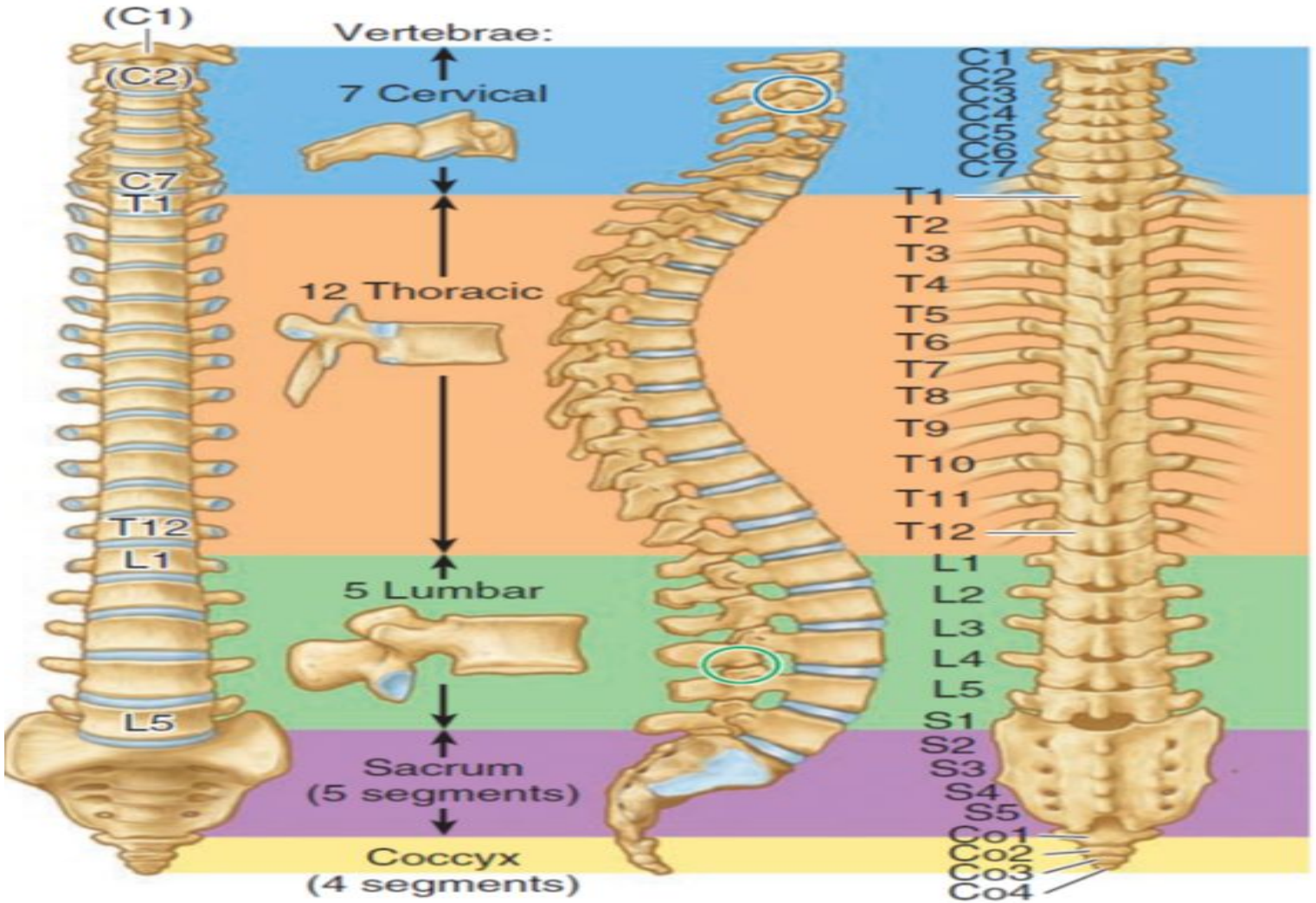

A) Anterior view

(B) Right lateral view

(C) Posterior view with vertebral ends of ribs

- The lumbosacral angle is located at the junction of the lumbar region of the vertebral column and sacrum.
- Significant motion occurs between only the ***superior 25 vertebrae***.
- ***The 5 sacral vertebrae*** (segments) are fused in adults to form the sacrum, and the 4 coccygeal vertebrae (segments) are fused to form the coccyx.
- The vertebrae gradually become larger as the vertebral column descends to the sacrum and then become progressively smaller toward the apex of the coccyx.
- These structural differences are related to the fact that the successive vertebrae bear increasing amounts of the body's weight. The vertebrae reach a maximum size immediately superior to the sacrum, which transfers the weight to the pelvic girdle at the sacroiliac joints.

- The presacral vertebral column is flexible because it consists of vertebrae joined together by semirigid intervertebral (IV) discs.
- The 25 cervical, thoracic, lumbar, and first sacral vertebrae also articulate at synovial ***zygapophysial joints***, which facilitate and control the vertebral column's flexibility.
- Vertebral bodies contribute approximately ***three-quarters*** of the height of the presacral vertebral column, and the fibrocartilage of IV discs contributes approximately ***one-quarter***.
- The shape and strength of the vertebrae and IV discs, ligaments, and muscles provide stability to the vertebral column.

Curvatures of Vertebral Column

- The vertebral column in adults has four curvatures: ***cervical***, ***thoracic***, ***lumbar,*** and ***sacral***.
- The thoracic and sacral (pelvic) curvatures (***kyphoses***) are concave anteriorly, whereas the cervical and lumbar curvatures (***lordoses***) are concave posteriorly.
- The thoracic and sacral curvatures are ***primary curvatures*** developing during the fetal period.
- Primary curvatures are retained throughout life as a consequence of differences in height between the anterior and the posterior parts of the vertebrae.
- The cervical and lumbar curvatures are ***secondary curvatures***, which begin to appear in the cervical region during the fetal period but do not become obvious until infancy.
- Secondary curvatures are maintained primarily by differences in thickness between the anterior and the posterior parts of the IV discs.
- The ***cervical curvature becomes prominent*** when an infant begins to hold his or her head erect.

Curvatures of Vertebral Column

Lateral view of normal curvatures of back

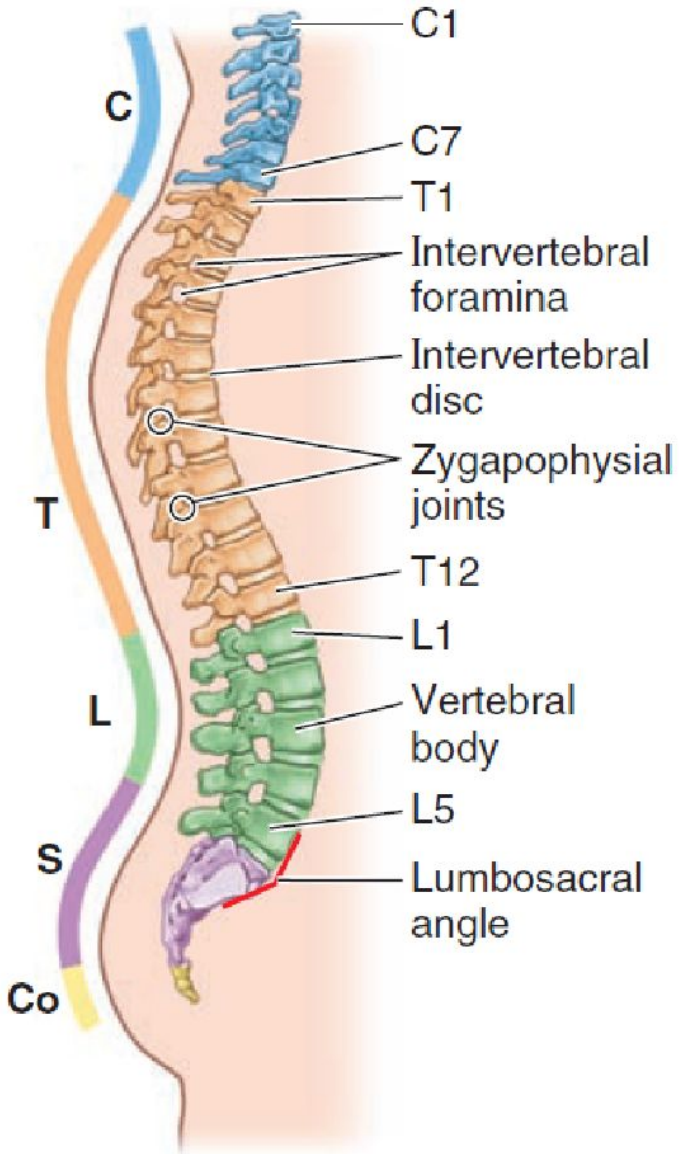

(D) Adult

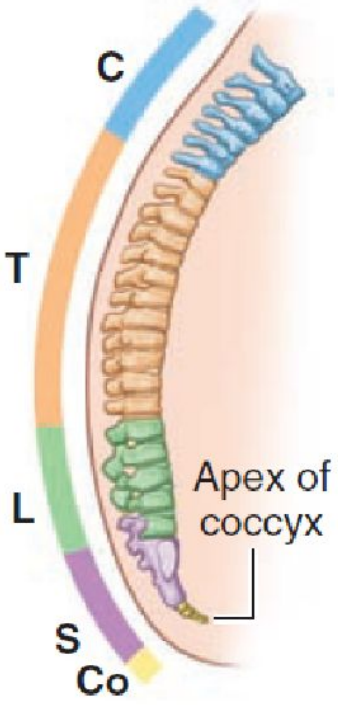

(E) Fetus

Lateral views

- The ***lumbar curvature becomes apparent*** when an infant begins to walk and assumes the upright posture. This curvature, generally more pronounced in females, ends at the ***lumbosacral angle***, formed at the junction of the L5 vertebra with the sacrum.
- The ***sacral curvature of females*** is reduced so that the coccyx protrudes less into the pelvic outlet (birth canal).
- The curvatures provide additional flexibility (***shock absorbing resilience***) to the vertebral column, augmenting that provided by the IV discs.
- Although the flexibility provided by the IV disc is ***passive*** and limited primarily by the zygapophysial (facet) joints and longitudinal ligaments, that provided by the curvatures is ***actively*** resisted by the contraction of muscle groups antagonistic to the movement.

Structure and Function of Vertebrae

- A typical vertebra consists of a ***vertebral body***, ***vertebral arch***, and ***seven processes***.
- ***The vertebral body*** (the anterior, more massive part of the vertebra) gives strength to the vertebral column and supports body weight. The size of vertebral bodies, especially from T4 inferiorly, increases to bear the progressively greater body weight. In life, most of the superior and inferior surfaces of vertebral bodies are covered with hyaline cartilage, which are remnants of the cartilaginous model from which the bone develops, except at the periphery, where there is a ring of smooth bone, the epiphysial rim.
- The cartilaginous remnants permit some diffusion of fluid between the IV disc and capillaries in the vertebral body.
- ***The vertebral arch*** lies posterior to the vertebral body and is formed by right and left pedicles and laminae.

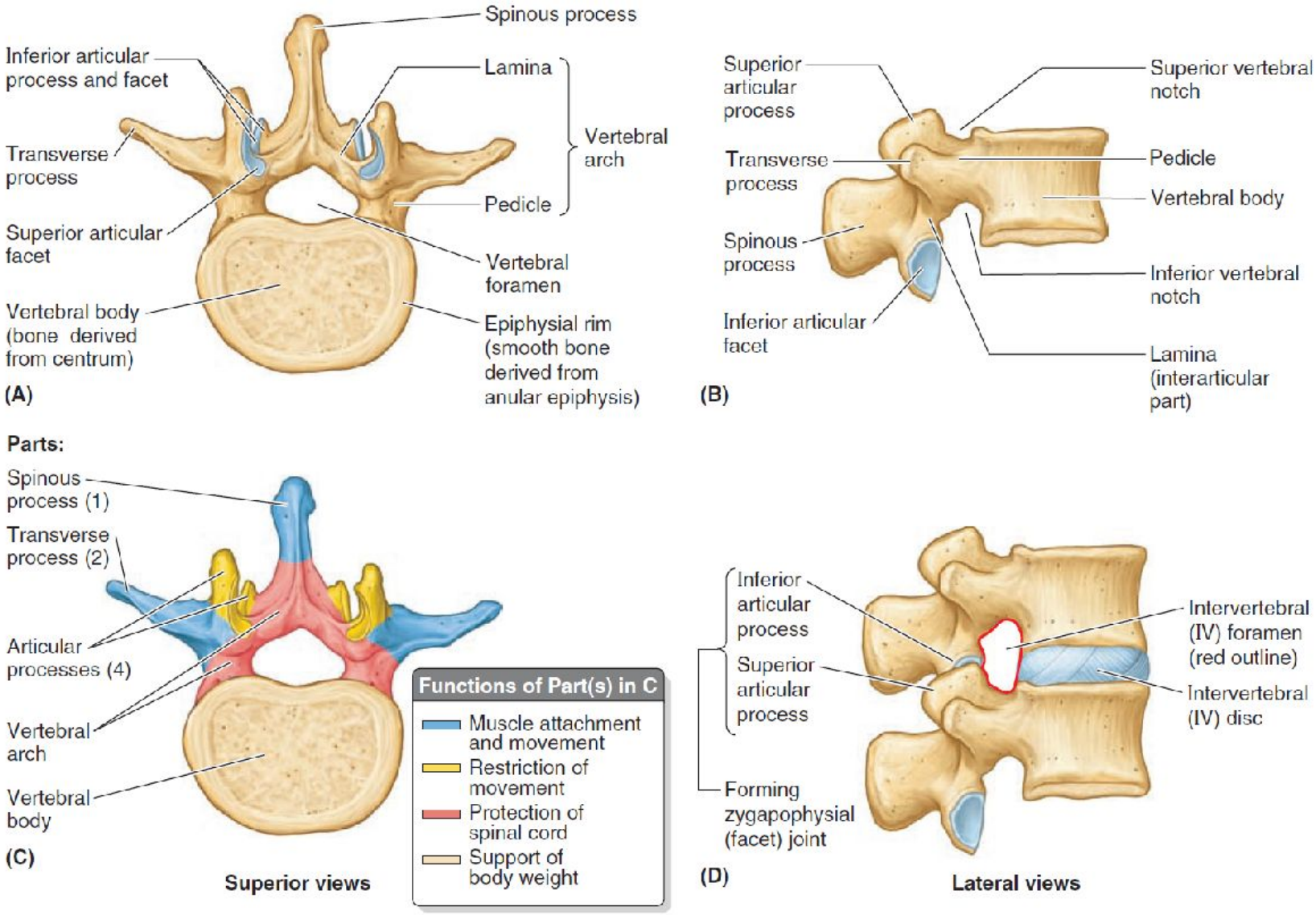
Spinous process
Inferior articular process and facet
Lamina
Vertebral arch
Transverse process
Pedicle
Superior articular facet
Vertebral foramen
Vertebral body (bone derived from centrum)
Epiphysial rim (smooth bone derived from anular epiphysis)
(A)
Superior articular process
Superior vertebral notch
Transverse process
Pedicle
Vertebral body
Spinous process
Inferior vertebral notch
Inferior articular facet
Lamina (interarticular part)
(B)
Parts:
Spinous process (1)
Transverse process (2)
Articular processes (4)
Vertebral arch
Vertebral body
(C)
Superior views
Functions of Part(s) in C
Muscle attachment and movement
Restriction of movement
Protection of spinal cord
Support of body weight
Inferior articular process
Superior articular process
Forming zygapophysial (facet) joint
Intervertebral (IV) foramen (red outline)
Intervertebral (IV) disc
(D)
Lateral views

- The ***pedicles*** are short, stout processes that join the vertebral arch to the vertebral body.
- The pedicles project posteriorly to meet two broad, flat plates of bone, called ***laminae***, which unite in the midline.
- The vertebral arch and the posterior surface of the vertebral body form the walls of the ***vertebral foramen.***
- The succession of vertebral foramina in the articulated column forms the ***vertebral canal***, which contains the spinal cord, meninges (protective membranes),n fat, spinal nerve roots, and vessels.
- The indentations formed by the projection of the body and articular processes superior and inferior to the pedicles are ***vertebral notches***
- The superior and inferior vertebral notches of adjacent vertebrae combine to form the ***IV foramina***, which give passage to spinal nerve roots and accompanying vessels and contain the spinal ganglia.

- The four articular processes are in apposition with corresponding processes of vertebrae superior and inferior to them, forming zygapophysial (facet) joints
- The direction of the articular facets on the articular processes determines the types of movements permitted and restricted between adjacent vertebrae of each region.
- ***Seven processes arise from the vertebral arch of a typical vertebra***
- ***One median spinous process*** projects posteriorly (and usually inferiorly) from the vertebral arch at the junction of the laminae.
- ***Two transverse processes*** project posterolaterally from the junctions of the pedicles and laminae.
- ***Four articular processes***—two superior and two inferior—also arise from the junctions of the pedicles and laminae, each bearing an articular surface (facet).

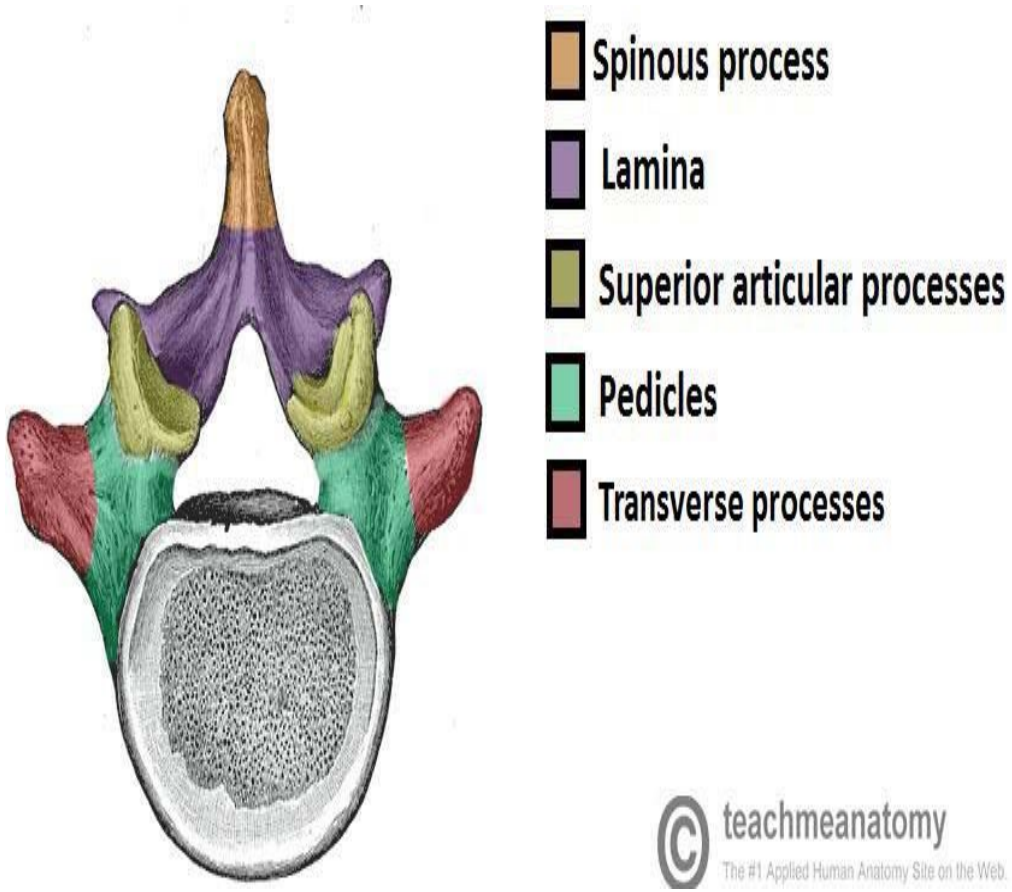
Spinous process
Lamina
Superior articular processes
Pedicles
Transverse processes
© teachmeanatomy
The #1 Applied Human Anatomy Site on the Web.

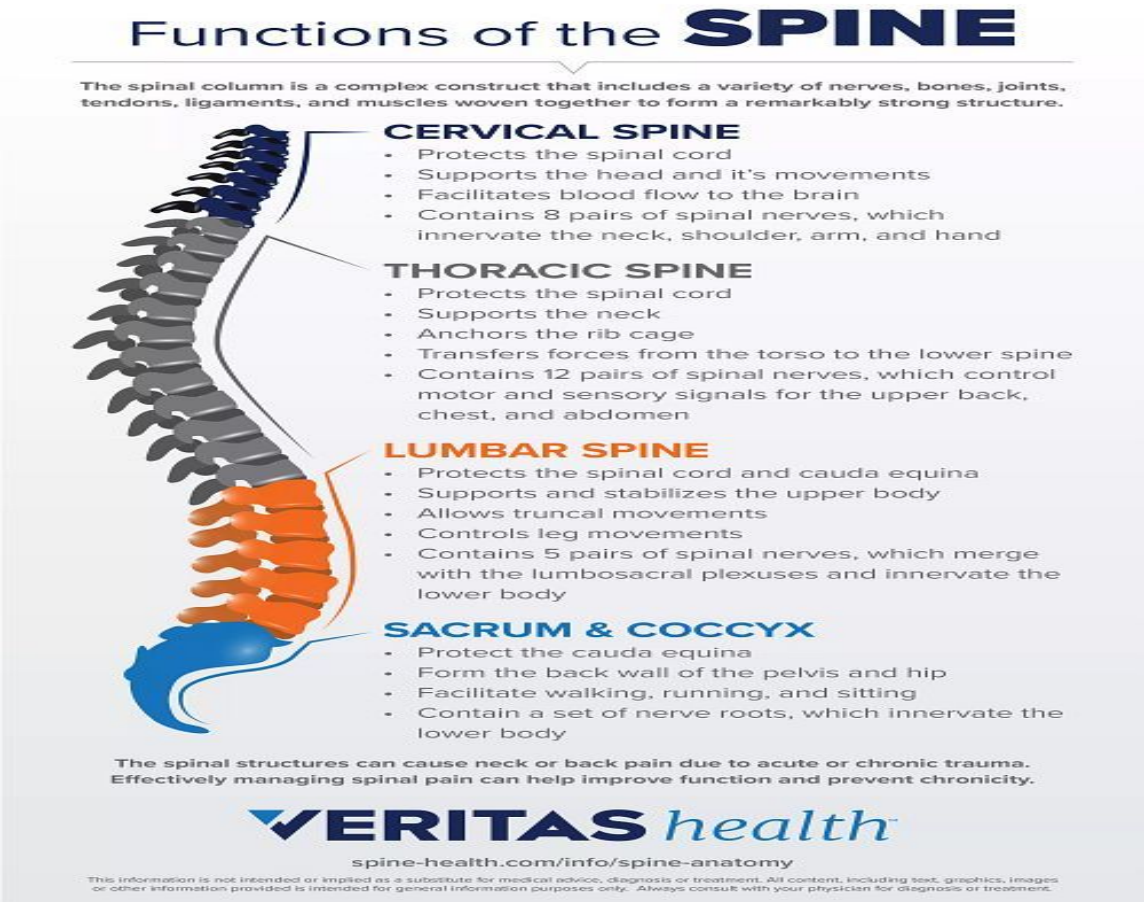
Functions of the SPINE
The spinal column is a complex construct that includes a variety of nerves, bones, joints, tendons, ligaments, and muscles woven together to form a remarkably strong structure.
CERVICAL SPINE
- Protects the spinal cord
- Supports the head and it's movements
- Facilitates blood flow to the brain
- Contains 8 pairs of spinal nerves, which innervate the neck, shoulder, arm, and hand
THORACIC SPINE
- Protects the spinal cord
- Supports the neck
- Anchors the rib cage
- Transfers forces from the torso to the lower spine
- Contains 12 pairs of spinal nerves, which control motor and sensory signals for the upper back, chest, and abdomen
LUMBAR SPINE
- Protects the spinal cord and cauda equina
- Supports and stabilizes the upper body
- Allows truncal movements
- Controls leg movements
- Contains 5 pairs of spinal nerves, which merge with the lumbosacral plexuses and innervate the lower body
SACRUM & COCCYX
- Protect the cauda equina
- Form the back wall of the pelvis and hip
- Facilitate walking, running, and sitting
- Contain a set of nerve roots, which innervate the lower body
The spinal structures can cause neck or back pain due to acute or chronic trauma. Effectively managing spinal pain can help improve function and prevent chronicity.
VERITAS health
spine-health.com/info/spine-anatomy
This information is not intended or implied as a substitute for medical advice, diagnosis or treatment. All content, including text, graphics, images or other information provided is intended for general information purposes only. Always consult with your physician for diagnosis or treatment.

Cervical vertebra

Part (Typical Vertebrae)	Distinctive Characteristics
Body	Small and wider from side to side than anteroposteriorly; superior surface is concave between adjacent (uncinate) processes; inferior surface is convex
Vertebral foramen	Large and triangular
Transverse processes	Foramina transversaria; small or absent in C7; vertebral arteries and accompanying venous and sympathetic plexuses pass through foramina (except C7, which transmits only small accessory vertebral veins); anterior and posterior tubercles
Articular processes	Superior facets directed superoposteriorly; inferior facets directed infero-anteriorly
Spinous process	C3–C5 short and bifid[a] (split in two parts); process of C6 is long but that of C7 is longer (C7 is called vertebra prominens)
Part (Atypical Vertebrae)	**Distinctive Characteristics**
Atlas (C1)	• Ring-like; somewhat kidney-shaped when viewed superiorly or inferiorly • No spinous process or body; consists of two lateral masses connected by anterior and posterior arches • Concave superior articular facets form atlanto-occipital joints with the occipital condyles; flat inferior facets meet with the C2 vertebra to form lateral atlanto-axial joints
Axis (C2)	• Strongest cervical vertebra • Distinguishing feature is the dens, which projects superiorly from its body and provides a pivot around which the atlas turns and carries the cranium • Articulates anteriorly with the anterior arch of the atlas and posteriorly with the transverse ligament of the atlas

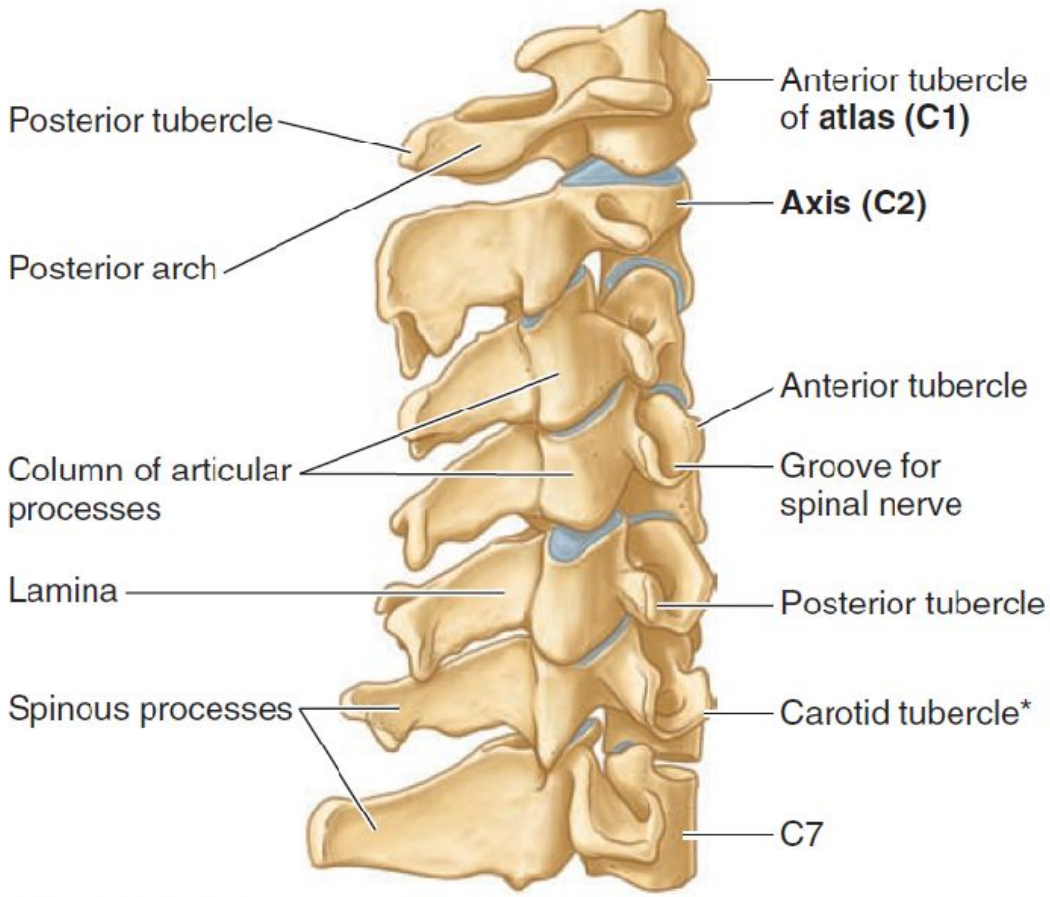

(A) Lateral view

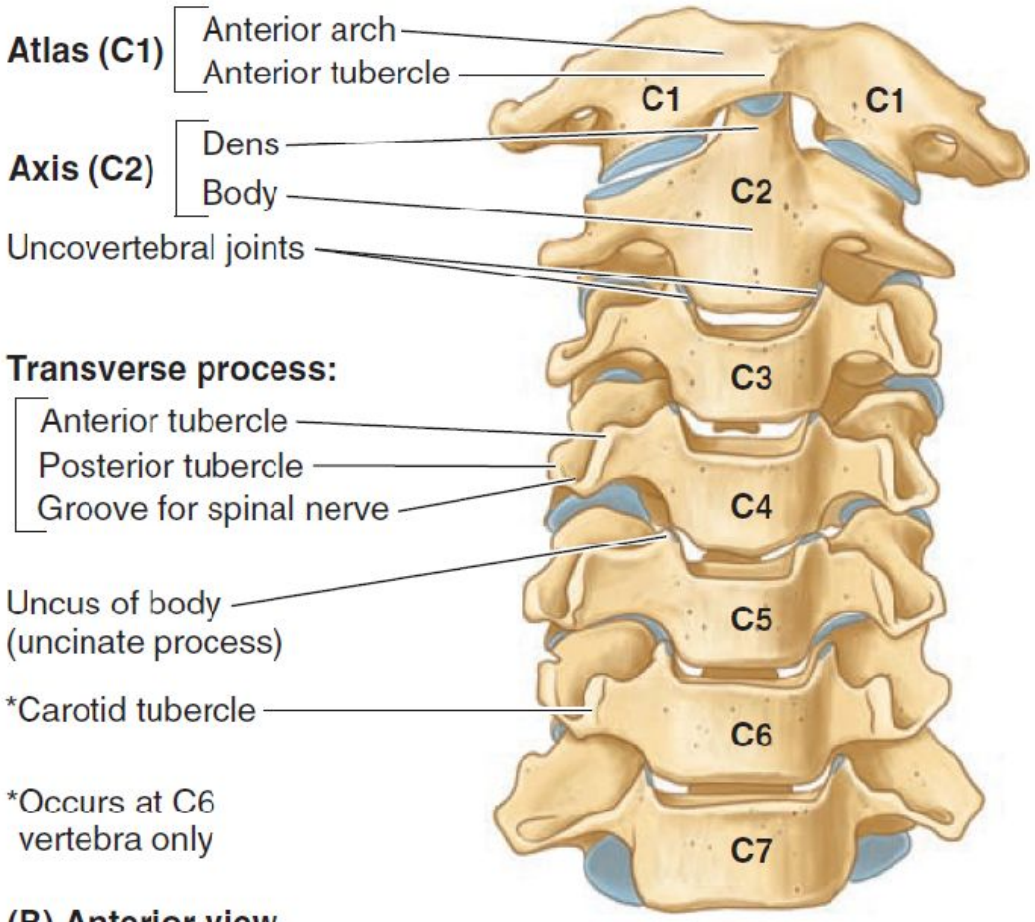

(B) Anterior view

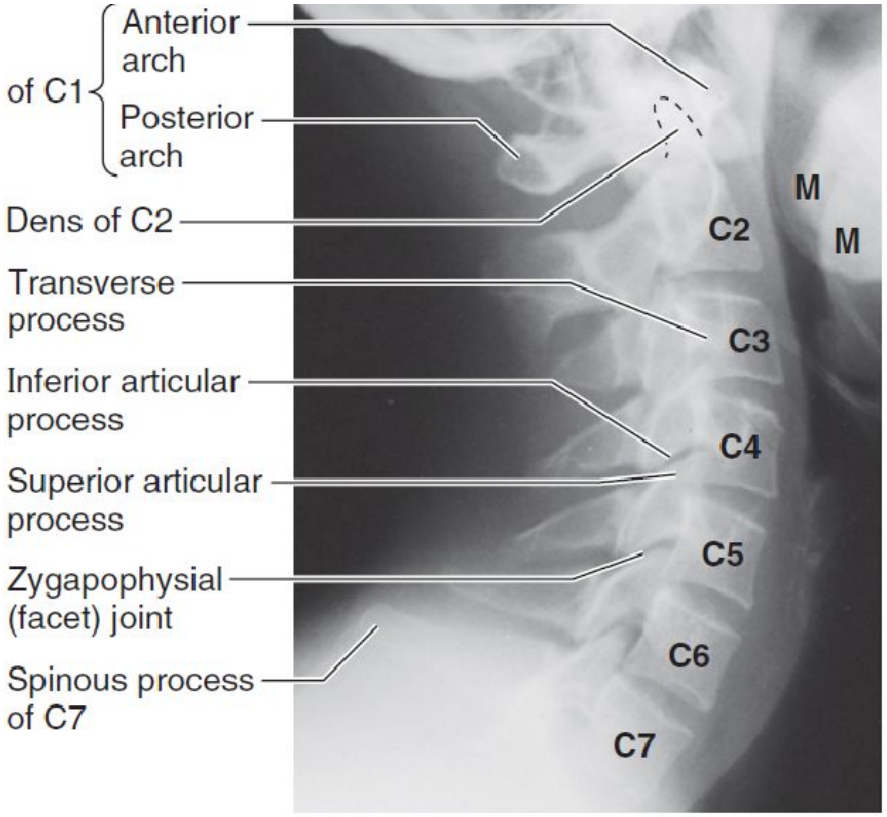

(C) Lateral view (M, mandible)

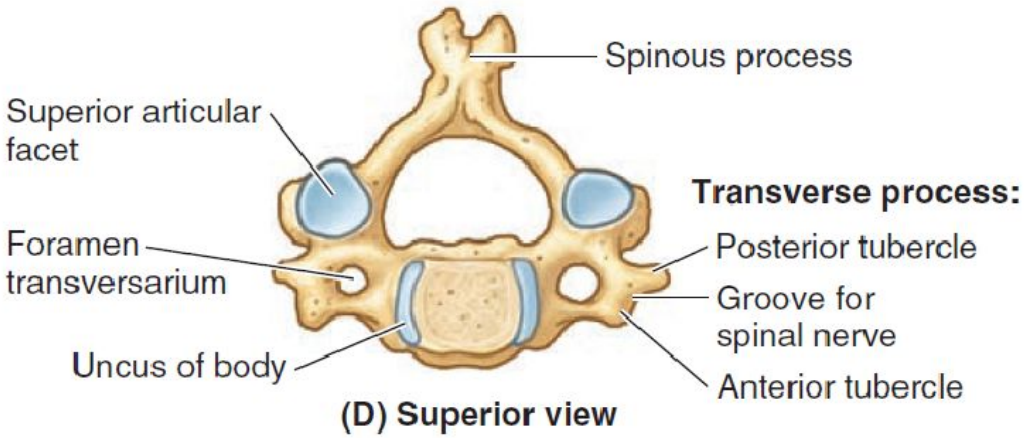

(D) Superior view

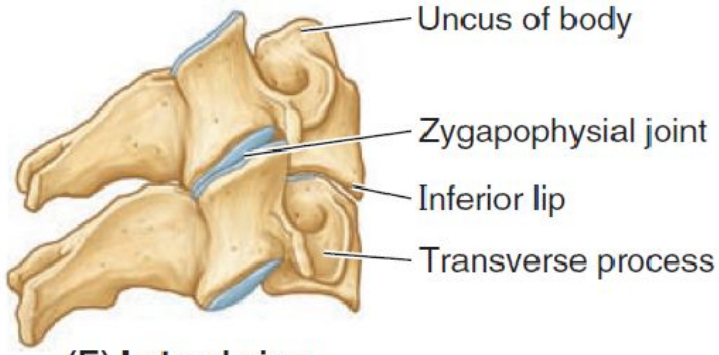

(E) Lateral view

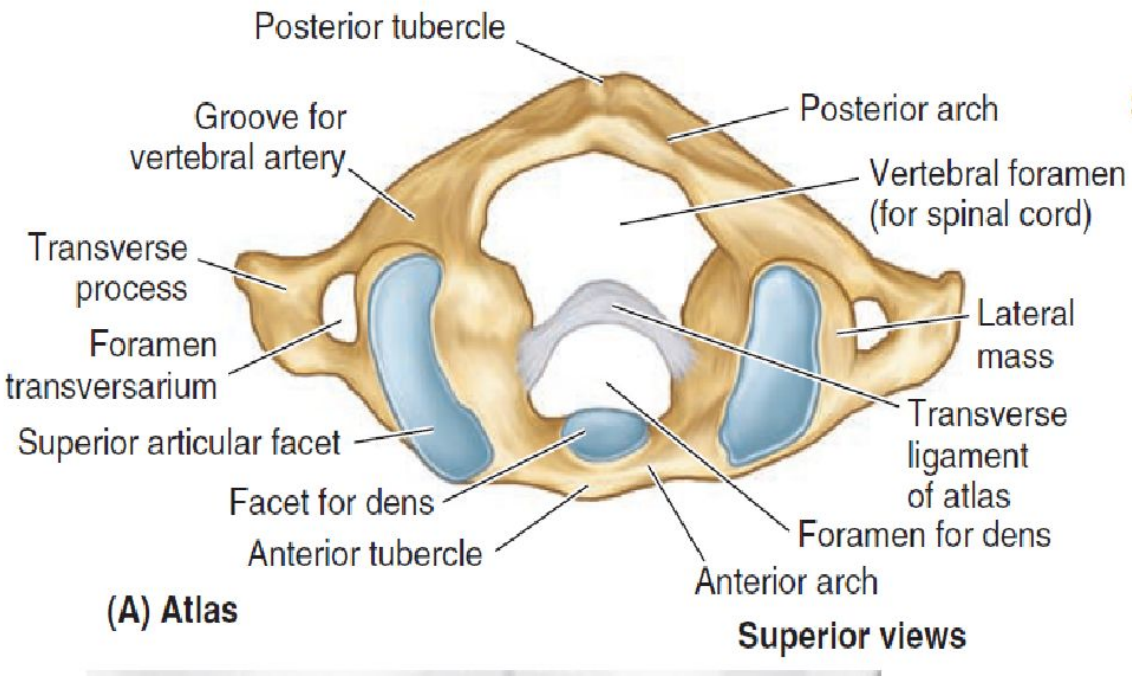
Posterior tubercle
Groove for vertebral artery
Posterior arch
Vertebral foramen (for spinal cord)
Transverse process
Foramen transversarium
Lateral mass
Superior articular facet
Transverse ligament of atlas
Facet for dens
Foramen for dens
Anterior tubercle
Anterior arch
(A) Atlas
Superior views

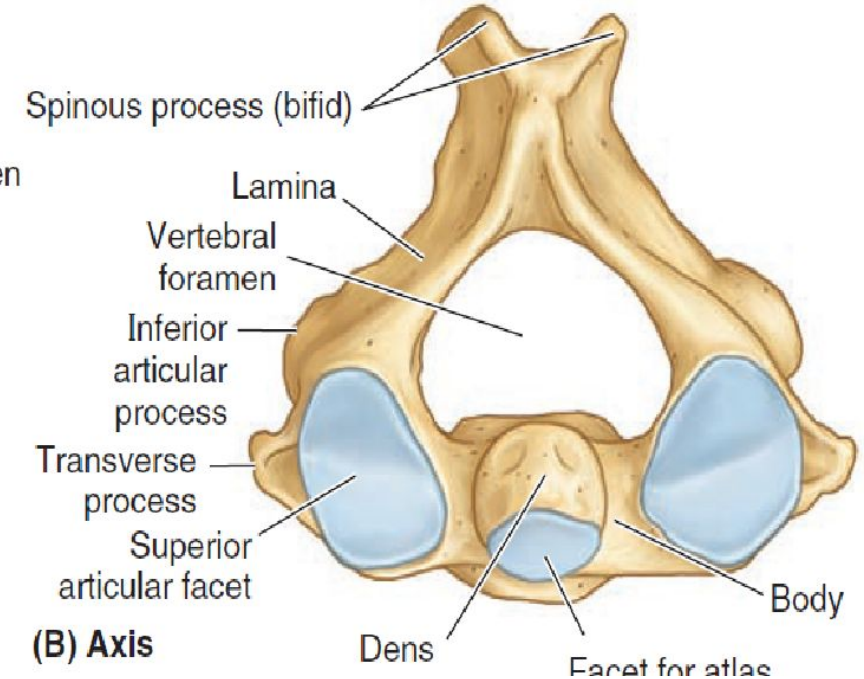
Spinous process (bifid)
Lamina
Vertebral foramen
Inferior articular process
Transverse process
Superior articular facet
Body
Dens
(B) Axis

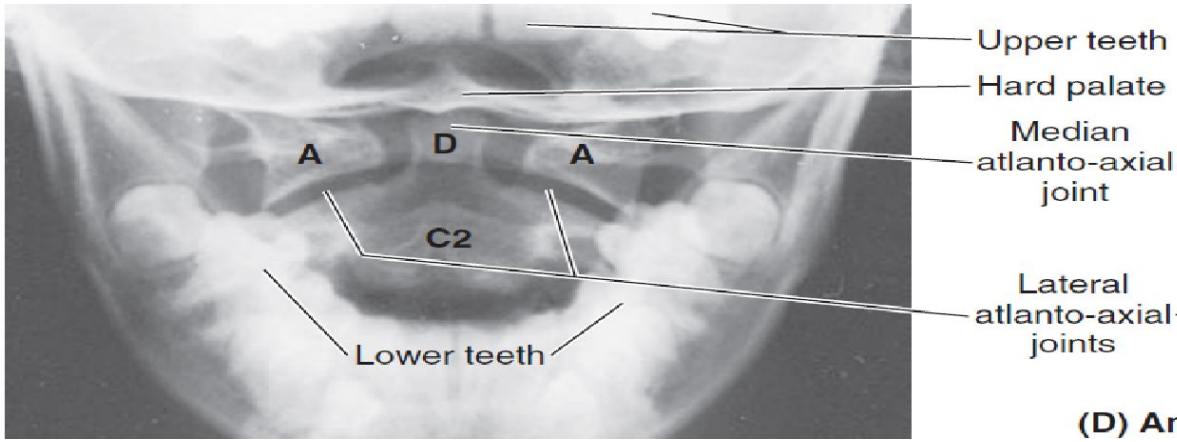
Upper teeth
Hard palate
Median atlanto-axial joint
A
D
A
C2
Lateral atlanto-axial joints
Lower teeth

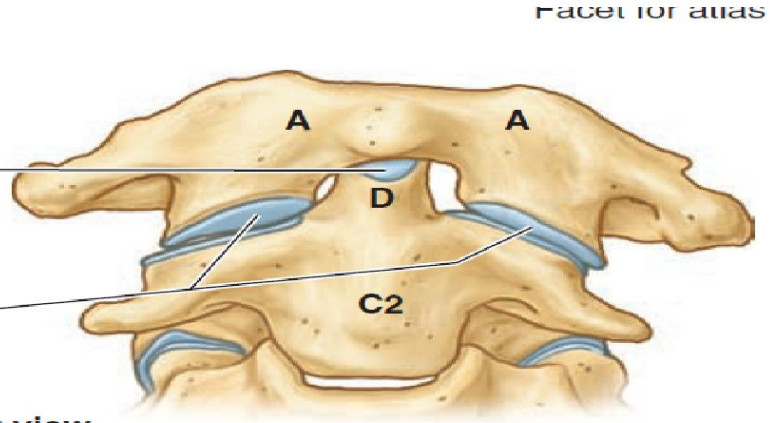
A
A
D
C2
(D) Anterior view

Thoracic vertebrae

Part	Distinctive Characteristics
Body	Heart-shaped; bears one or two bilateral costal facets for articulation with head of rib (*H*)
Vertebral foramen	Circular and smaller than those in cervical and lumbar regions
Transverse process (*TP*)	Long and strong; extends posterolaterally; length diminishes from T1–T12; those of T1–T10 have transverse costal facets for articulation with tubercle of rib
Articular processes	Superior articular facets directed posteriorly and slightly laterally; inferior articular facets directed anteriorly and slightly medially
Spinous process (*SP*)	Long; slopes postero-inferiorly, overlapping subadjacent vertebral body (sometimes completely)

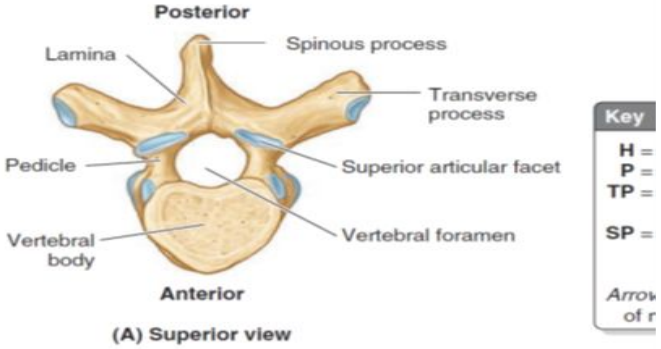

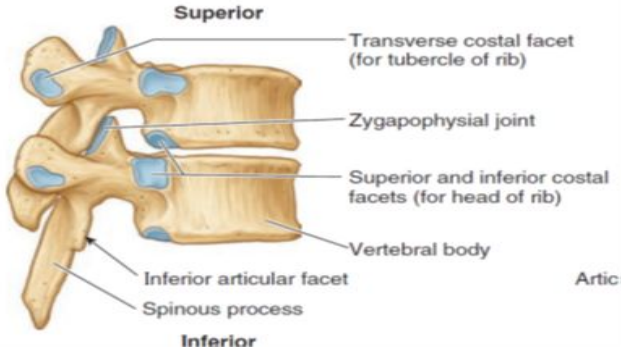

Lumber vertebrae

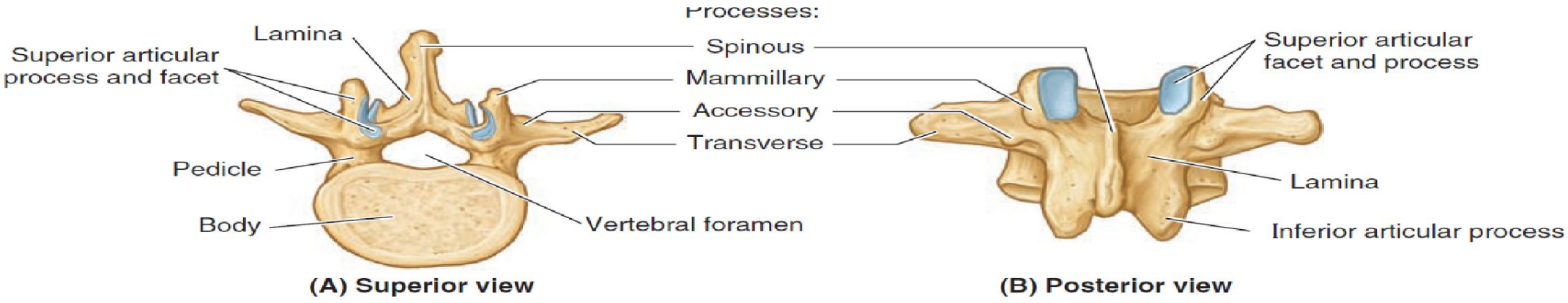

Part	Distinctive Characteristics
Body	Massive; kidney-shaped when viewed superiorly; larger and heavier than those of other regions
Vertebral foramen	Triangular; larger than in thoracic vertebrae and smaller than in cervical vertebrae
Transverse processes	Long and slender; accessory process on posterior surface of base of each process
Articular processes	Superior articular facets directed posteromedially (or medially); inferior articular facets directed anterolaterally (or laterally); mammillary process on posterior surface of each superior articular process
Spinous process	Short and sturdy; hatchet-shaped

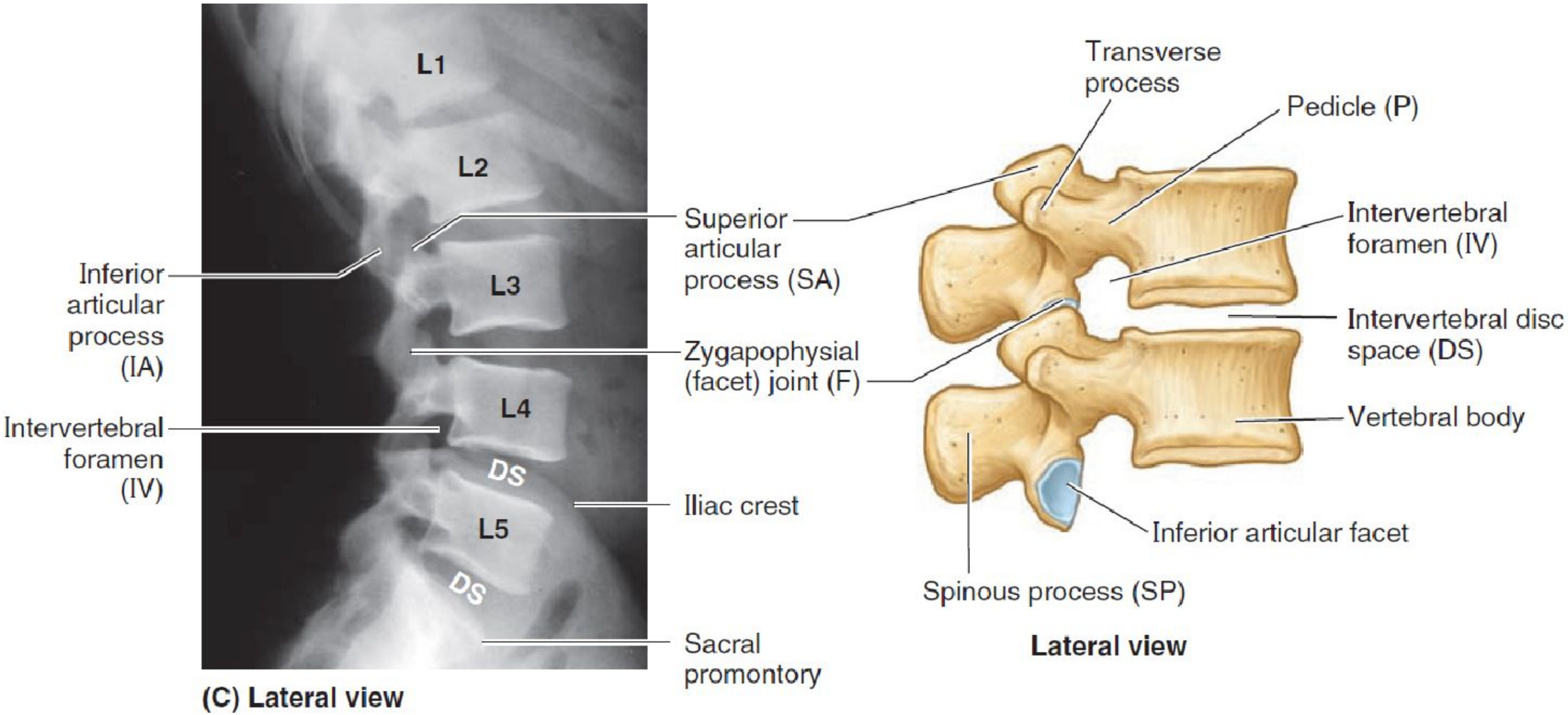
L1
L2
L3
L4
DS
L5
DS
Superior articular process (SA)
Inferior articular process (IA)
Zygapophysial (facet) joint (F)
Intervertebral foramen (IV)
Iliac crest
Sacral promontory
(C) Lateral view
Transverse process
Pedicle (P)
Intervertebral foramen (IV)
Intervertebral disc space (DS)
Vertebral body
Inferior articular facet
Spinous process (SP)
Lateral view

SACRUM AND COCCYX

- The large, wedge-shaped sacrum in adults is composed of five fused sacral vertebrae.
- The sacrum provides strength and stability to the pelvis and transmits body weight to the pelvic girdle through the sacro-iliac joints.
- The base of the sacrum is formed by the superior surface of the S1 vertebra. Its superior articular processes articulate with the inferior articular processes of the L5 vertebra. The projecting anterior edge of the body of the first sacral vertebra is the sacral promontory.
- On the pelvic and dorsal surfaces are four pairs of sacral foramina for the exit of the rami of the first four sacral nerves and the accompanying vessels.
- The pelvic surface of the sacrum is smooth and concave.

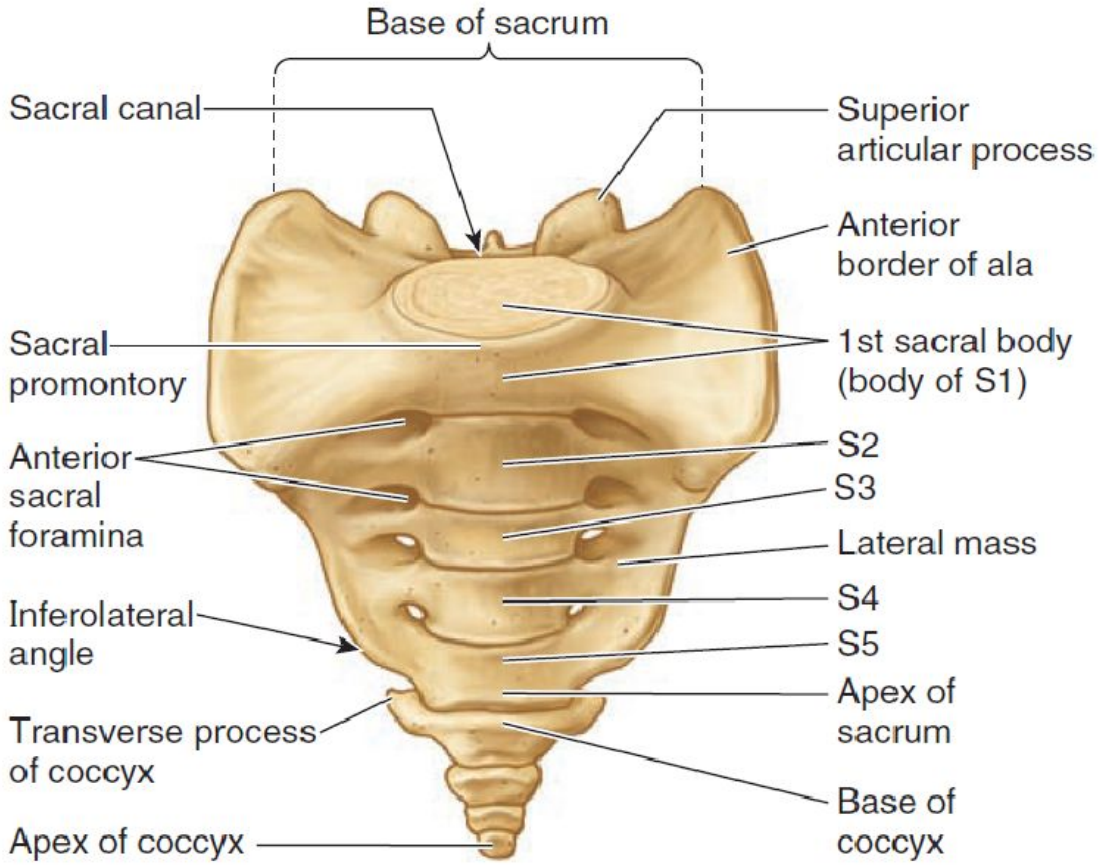

(A) Antero-inferior view

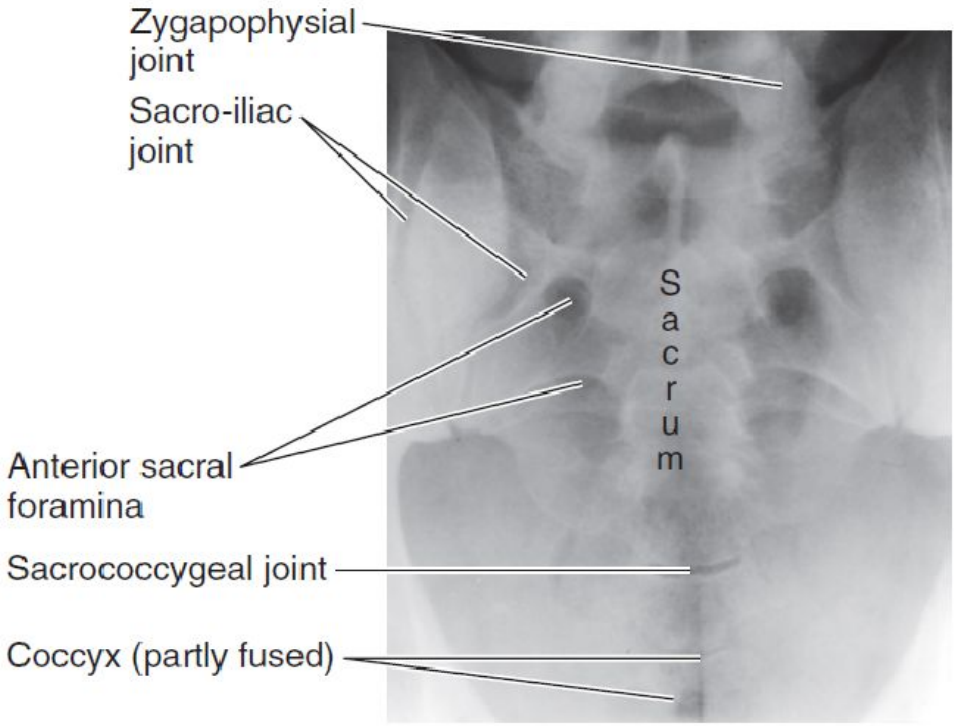

(B) Postero-anterior projection, anteroposterior view

- The four transverse lines indicate where fusion of the sacral vertebrae occurred.
- The posterior surface of the sacrum is rough and convex.
- The fused spinous processes form the median sacral crest. The fused articular processes form the intermediate sacral crests, and the fused tips of the transverse processes form the lateral sacral crests. The inverted U-shaped sacral hiatus results from the absence of the laminae and spinous processes of the S4 and S5 vertebrae. The hiatus leads into the sacral canal, the inferior end of the vertebral canal.
- The sacral cornua (L. horns), representing the inferior articular processes of the S5 vertebra, project inferiorly on each side of the sacral hiatus and are a helpful guide to its location.
- The lateral surface of the sacrum has an ear-shaped (auricular) articular surface that participates in the sacro-iliac joint. The four vertebrae of the tapering coccyx are remnants of the skeleton of the embryonic tail-like caudal eminence.
- The distal three vertebrae fuse during middle life to form the coccyx, a beak-like bone that articulates with the sacrum.

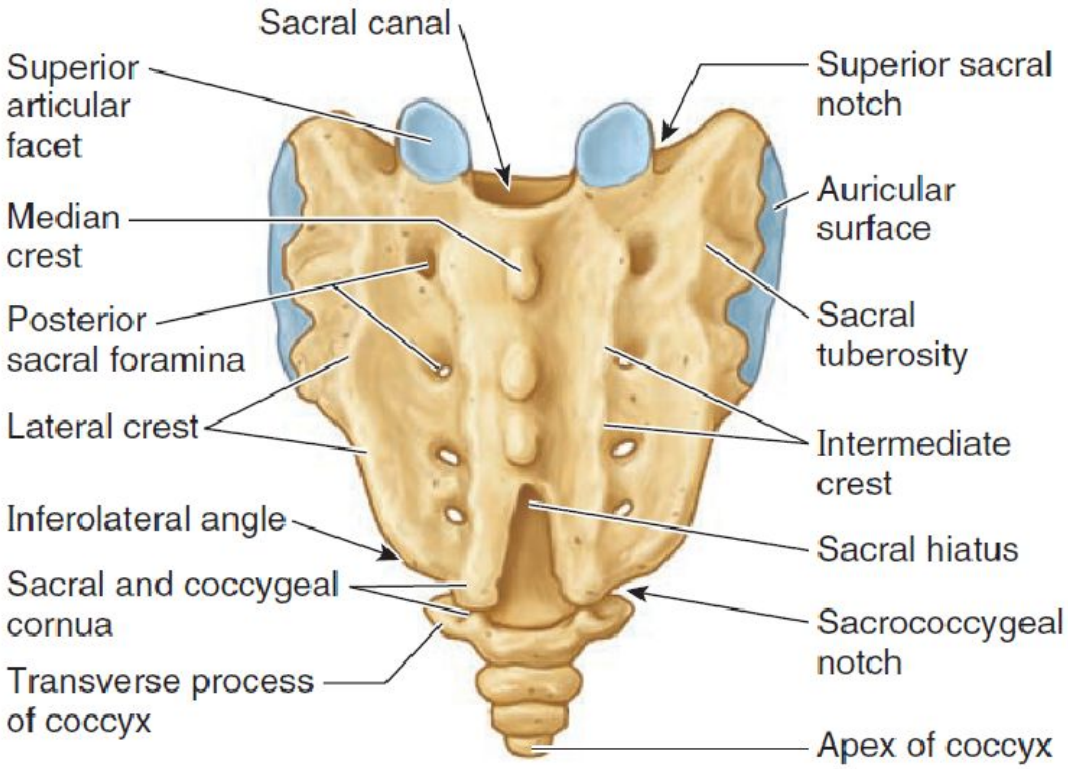

(C) Posterosuperior view

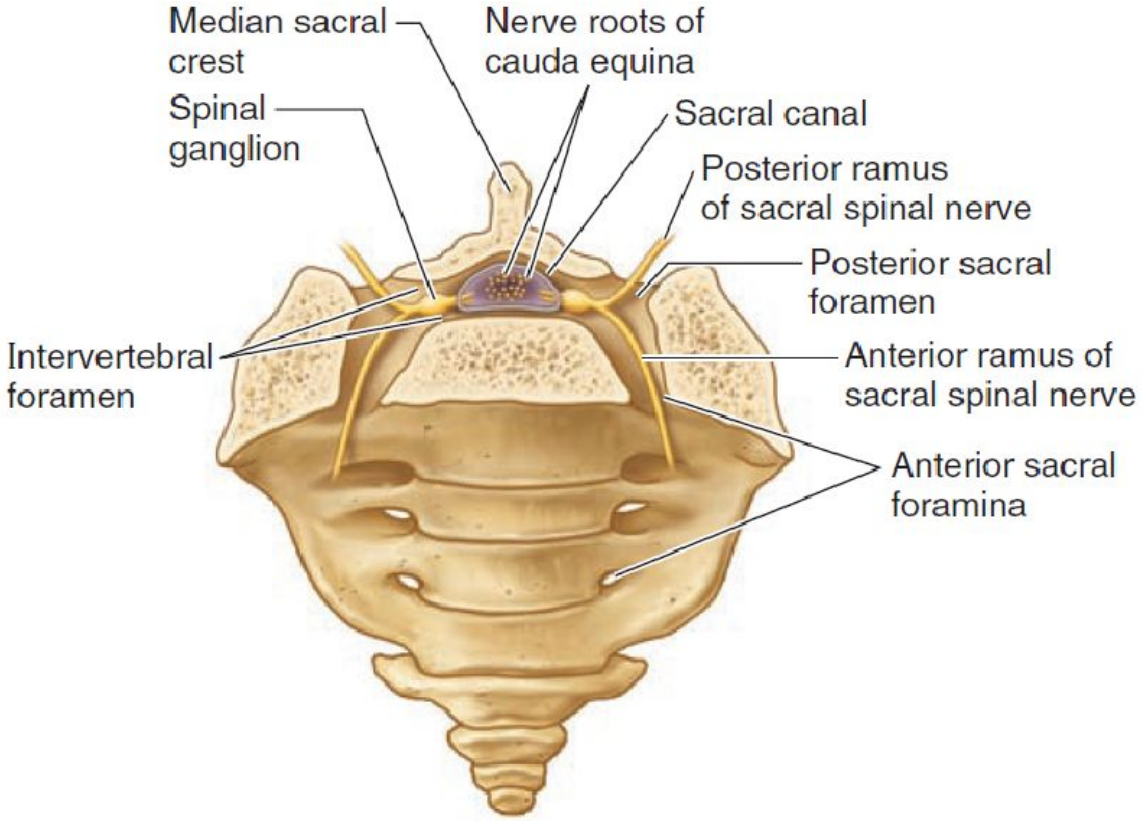

(D) Anerior view

Joints of Vertebral Column

- ***JOINTS OF VERTEBRAL BODIES***

- The joints of the vertebral bodies are symphyses (secondary cartilaginous joints) designed for weight bearing and strength.
- ***Intervertebral discs***
- The articulating surfaces of adjacent vertebrae are connected by IV discs and ligaments.
- The IV discs, interposed between the bodies of adjacent vertebrae, provide strong attachments between the vertebral bodies. As well as permitting movement between adjacent vertebrae the discs have resilient deformability, which allows them to serve as shock absorbers.
- Each IV disc consists of an annulus fibrosus, an outer fibrous part, and a gelatinous central mass, the nucleus pulposus.

- ***The annulus fibrosus***
- is a ring consisting of concentric lamellae of fibrocartilage forming the circumference of the IV disc. The anuli insert into the smooth, rounded epiphysial rims on the articular surfaces of the vertebral bodies
- The lamellae of the anulus thicken with age and often develop fissures and cavities. Because the lamellae are thinner and less numerous posteriorly, the nucleus pulposus is not centered in the disc but is more posteriorly placed
- ***The nucleus pulposus***
- is the central core of the IV disc. At birth, the nuclei are about 85% water. The pulpy nuclei become broader when compressed and thinner when tensed or stretched. Compression and tension occur simultaneously in the same disc during movement of the vertebral column (e.g., anterior and lateral flexion, extension, rotation); the turgid nucleus acts as a semifluid fulcrum .
- The nuclei pulposi dehydrate with age and lose elastin and proteoglycans while gaining collagen, eventually becoming dry and granular. As a result, the IV discs lose their turgor, becoming thinner, stiffer, and more resistant to deformation.

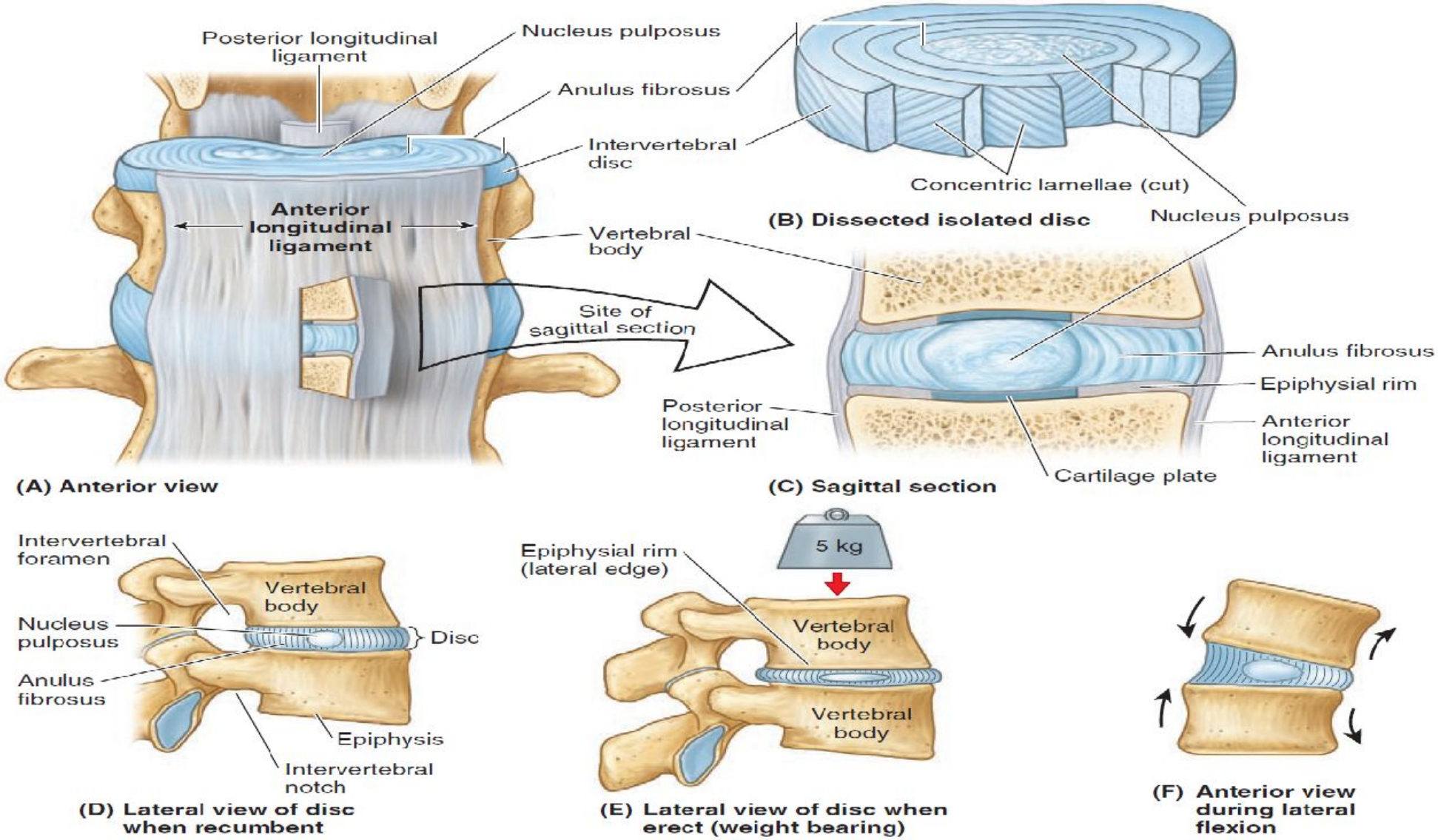
Posterior longitudinal ligament
Nucleus pulposus
Anulus fibrosus
Intervertebral disc
Anterior longitudinal ligament
Vertebral body
Site of sagittal section
(A) Anterior view
Concentric lamellae (cut)
(B) Dissected isolated disc
Nucleus pulposus
Anulus fibrosus
Epiphysial rim
Posterior longitudinal ligament
Anterior longitudinal ligament
Cartilage plate
(C) Sagittal section
Intervertebral foramen
Vertebral body
Nucleus pulposus
Disc
Anulus fibrosus
Epiphysis
Intervertebral notch
(D) Lateral view of disc when recumbent
Epiphysial rim (lateral edge)
5 kg
Vertebral body
Vertebral body
(E) Lateral view of disc when erect (weight bearing)
(F) Anterior view during lateral flexion

- The nucleus pulposus is ***avascular***. It receives its nourishment by diffusion from blood vessels at the periphery of the anulus fibrosus and vertebral body.
- There is no IV disc between the C1 (atlas) and C2 (axis) vertebrae. The most inferior functional disc is between the L5 and S1 vertebrae.
- The discs vary in thickness in different regions. They are thicker in the cervical and lumbar regions and thinnest in the superior thoracic region
- ***Uncovertebral "joints" (of Luschka)***
- are located between the uncus of the bodies (uncinate processes) of the C3–C6 vertebrae and the beveled inferolateral surfaces of the vertebral bodies superior to them.
- The joints are at the lateral and posterolateral margins of the IV discs. The articulating surfaces of these joint-like structures are covered with cartilage and contain a capsule filled with fluid. They are considered to be synovial joints by some; others consider them to be degenerative spaces (fissures) in the discs occupied by extracellular fluid.
- The uncovertebral joints are frequent sites of spur formation (projecting processes of bone) that may cause neck pain.

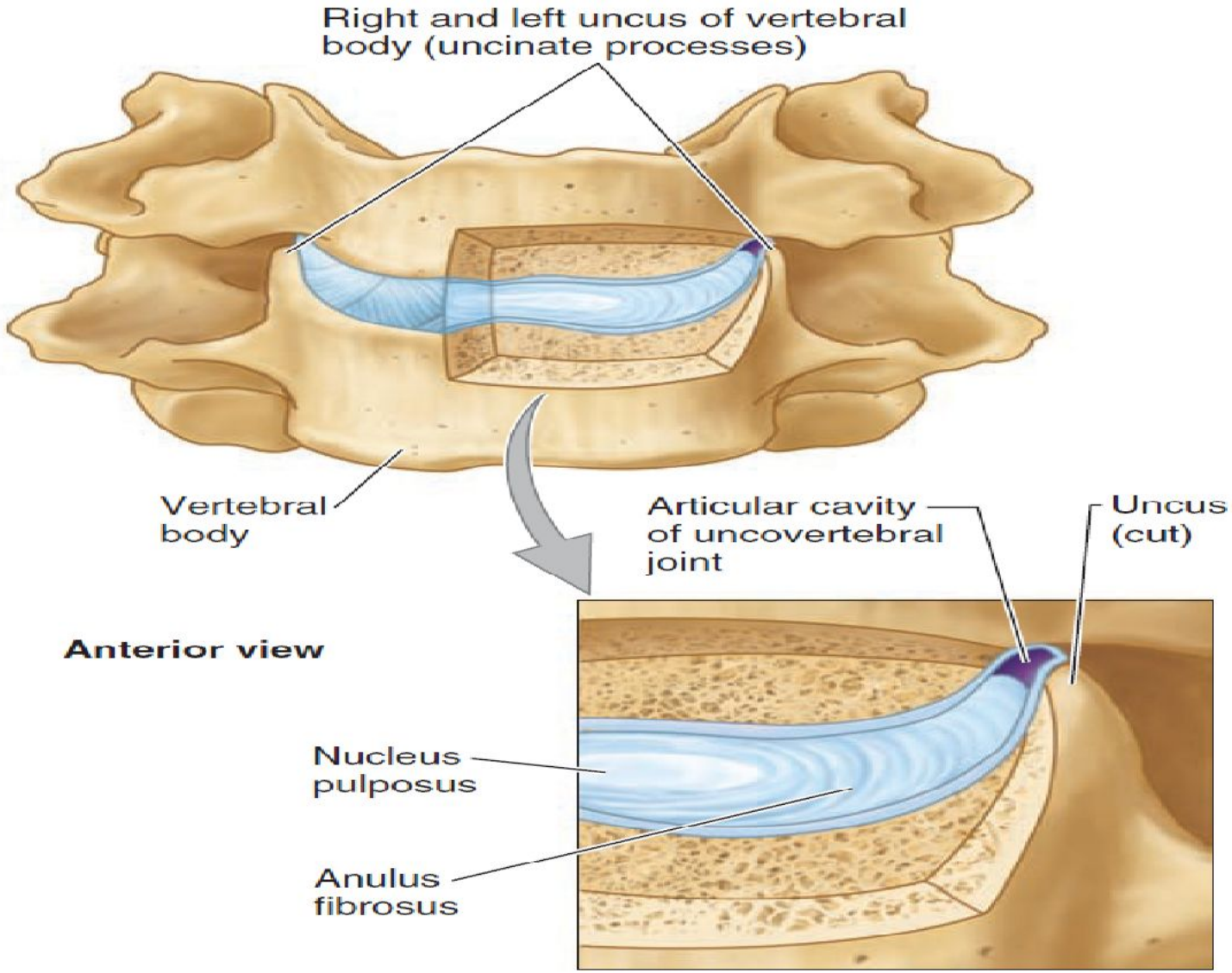
Right and left uncus of vertebral body (uncinate processes)
Vertebral body
Articular cavity of uncovertebral joint
Uncus (cut)
Anterior view
Nucleus pulposus
Anulus fibrosus

- ***Longitudinal Ligaments of the Spine***
- 2 major ligaments, an anterior and posterior longitudinal ligament
- The ligaments run along the longitudinal axis of the vertebral column. The anterior longitudinal ligament is the stronger of the 2
- Other additional ligaments support the integrity of the vertebral column
- ***The Anterior Longitudinal Ligament of the Vertebral Column***
- It is a flat band that broadens as it passes downwards, it extends from the anterior tubercle of the atlas to the front of the upper part of the sacrum
- It is firmly united to the periosteum of the vertebral bodies
- It is free over the intervertebral discs
- It is the stronger of the 2 longitudinal ligaments of the vertebral column

- ***The Posterior Longitudinal Ligament of the Vertebral Column***
- Extends from the back of the body of the axis (2nd cervical vertebra) to the canal of the sacrum
- It is continued above the body of the axis as the ‘membrane tectoria’.it narrows gradually as it passes downwards and has serrated margins
- The serrations are broadest over the intervertebral disc to which they are firmly united
- The ligament narrows over the vertebral bodies.
- They are separated from the vertebral bodies by the emerging basivertebral veins.

Ligamentum flava

- Yellow in colour due to its high content of elastic fibres
- It joins the lamina of adjacent vertebrae. They are attached to the front of the upper lamina and to the back of the lower lamina, they are starched by the flexion of the spine

Supraspinous ligament

- Joins the tips of adjacent spinous processes, they are strong bands of white fibrous tissues
- They are lax in the extended spines, full flexion effectively prevents erector spinae muscles from the extending spine
- In flexion of the vertebral column, they are drawn taut to mechanically support the vertebral column

- ***Interspinous ligament***
- They are relatively weak sheets of fibrous tissue
- They unite spnous processes along their adjacent borders
- They are well developed only in the lumbar region
- They fuse with supraspinous ligaments
- ***Ligamentume Nuchae (nuchal ligament)***
- Proximal attachment : occipital protuberance on the back of the skull
- Distal attachment : thoracic spinal ligaments: ***interspinous and supraspinous ligaments***
- Intermediate attachments: the spinous processes of all cervical vertebrae
- It maintains the secondary curvature of the cervical spine
- It helps the cervical spine support the head
- It acts as a major site of attachment of neck and trunk muscles such as trapezius and the rhomboids.

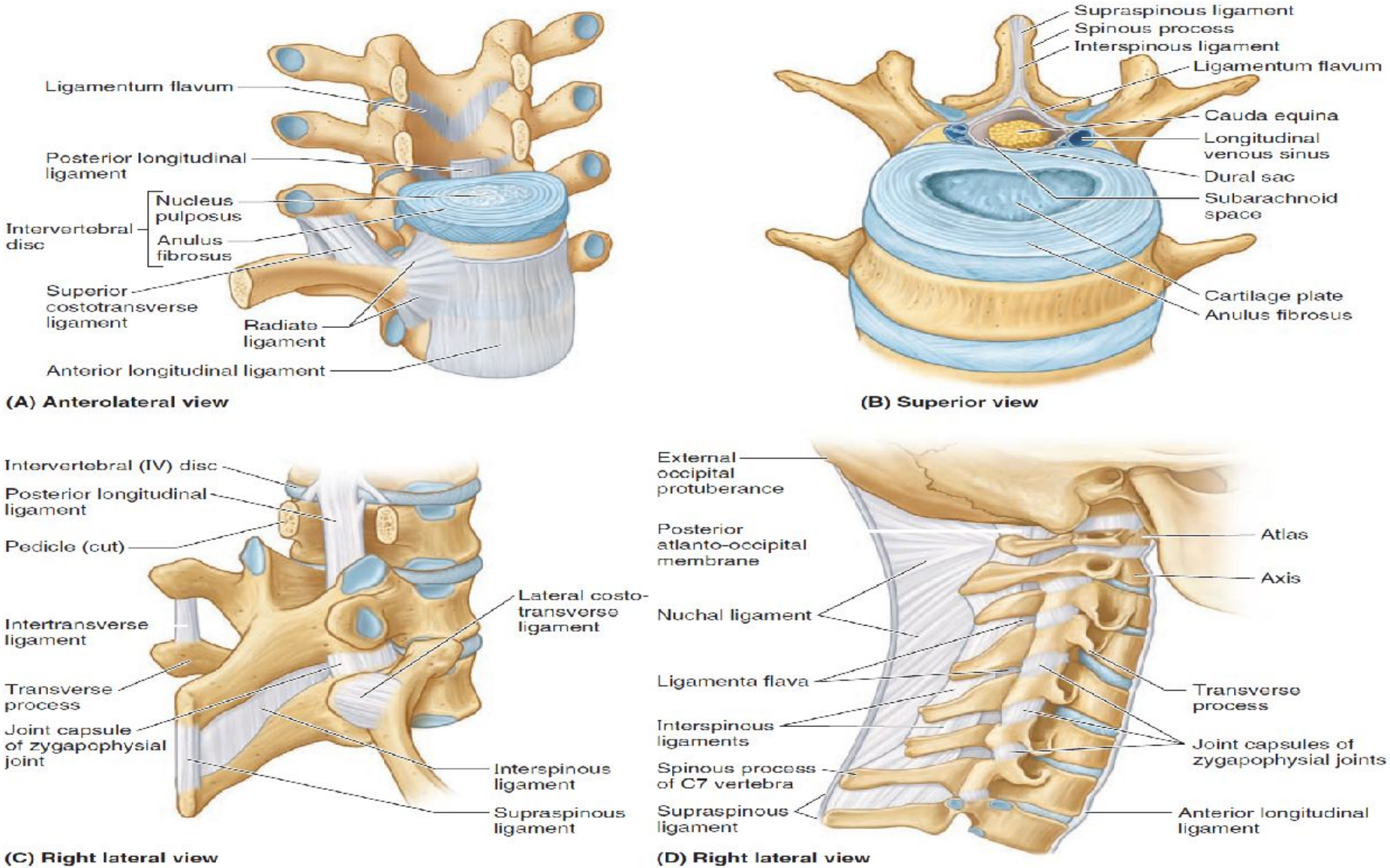
Ligamentum flavum
Posterior longitudinal ligament
Nucleus pulposus
Intervertebral disc
Anulus fibrosus
Superior costotransverse ligament
Radiate ligament
Anterior longitudinal ligament
(A) Anterolateral view
Supraspinous ligament
Spinous process
Interspinous ligament
Ligamentum flavum
Cauda equina
Longitudinal venous sinus
Dural sac
Subarachnoid space
Cartilage plate
Anulus fibrosus
(B) Superior view
Intervertebral (IV) disc
Posterior longitudinal ligament
Pedicle (cut)
Intertransverse ligament
Transverse process
Joint capsule of zygapophysial joint
Lateral costo-transverse ligament
Interspinous ligament
Supraspinous ligament
(C) Right lateral view
External occipital protuberance
Posterior atlanto-occipital membrane
Nuchal ligament
Ligamenta flava
Interspinous ligaments
Spinous process of C7 vertebra
Supraspinous ligament
Atlas
Axis
Transverse process
Joint capsules of zygapophysial joints
Anterior longitudinal ligament
(D) Right lateral view

Movements of Vertebral Column

- Movements of the vertebral column include flexion, extension, lateral flexion, and rotation .
- The range of movement of the vertebral column varies according to the region and the individual. The normal range of movement possible in healthy young adults is typically reduced by 50% during advanced age.
- The mobility of the column results primarily from the compressibility and elasticity of the IV discs
- The movements are not produced exclusively by the back muscles. They are assisted by gravity and the action of the anterolateral abdominal muscles. Movements between adjacent vertebrae occur at the resilient IV discs and at the zygapophysial joints.
- Movements of the vertebral column are freer in the cervical and lumbar regions than in the thoracic region. Flexion, extension, lateral flexion, and rotation of the neck is especially free ***because the***

- IV discs, although thin relative to most other discs, are thick relative to the small size of the vertebral bodies at this level
- Articular surfaces of the zygapophysial joints are relatively large and the joint planes are almost horizontal.
- Joint capsules of the zygapophysial joints are loose.
- Neck is relatively slender (with less surrounding soft tissue bulk).

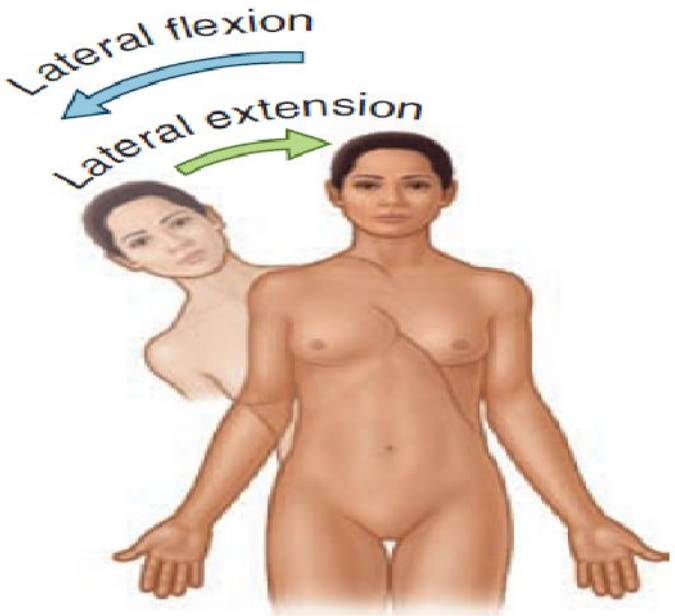
Lateral flexion
Lateral extension

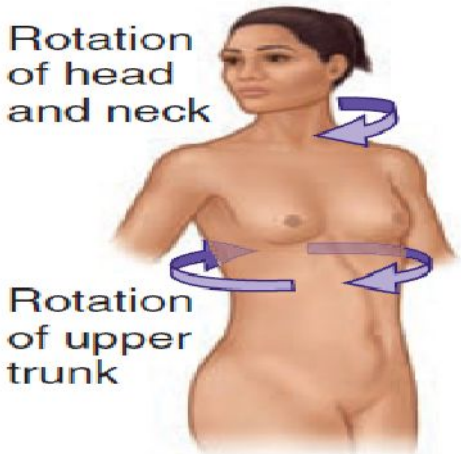
Rotation of head and neck
Rotation of upper trunk

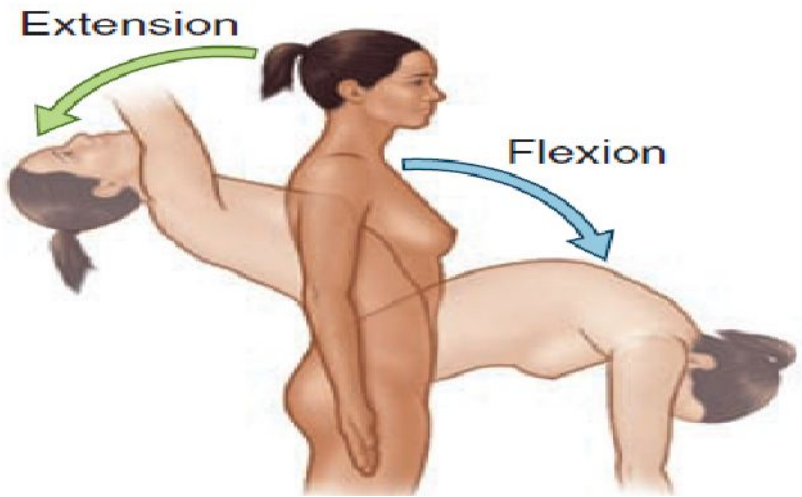
Extension
Flexion

- ***The range of movement of the vertebral column is limited by the***

- Thickness, elasticity, and compressibility of the IV discs
- Shape and orientation of the articular facets
- Tension of the joint capsules of the above joints
- Resistance of the back muscles and ligaments (such as the ligamenta flava and the posterior longitudinal ligament)
- Attachment to the thoracic (rib) cage
- Bulk of the surrounding tissues

Vasculature of Vertebral Column

- Vertebrae are supplied by periosteal and equatorial branches of the major cervical and segmental arteries and their spinal branches.
- ***Spinal branches supplying the vertebrae are branches of the***

- Vertebral and ascending cervical arteries in the neck
- Posterior intercostal arteries in the thoracic region
- Subcostal and lumbar arteries in the abdomen
- Iliolumbar and lateral and medial sacral arteries in the pelvis

- ***Periosteal and equatorial branches*** arise from these arteries as they cross the external (anterolateral) surfaces of the vertebrae.

- ***Spinal branches*** enter the IV foramina and divide into ***anterior and posterior vertebral canal branches*** that pass to the vertebral body and vertebral arch, respectively, and give rise to ascending and descending branches that anastomose with spinal canal branches of adjacent levels.
- ***Anterior vertebral canal branches*** send nutrient arteries into the vertebral bodies.
- The spinal branches continue as ***terminal radicular arteries*** distributed to the posterior and anterior roots of the spinal nerves and their coverings or as ***segmental medullary arteries*** that continue to the spinal cord.

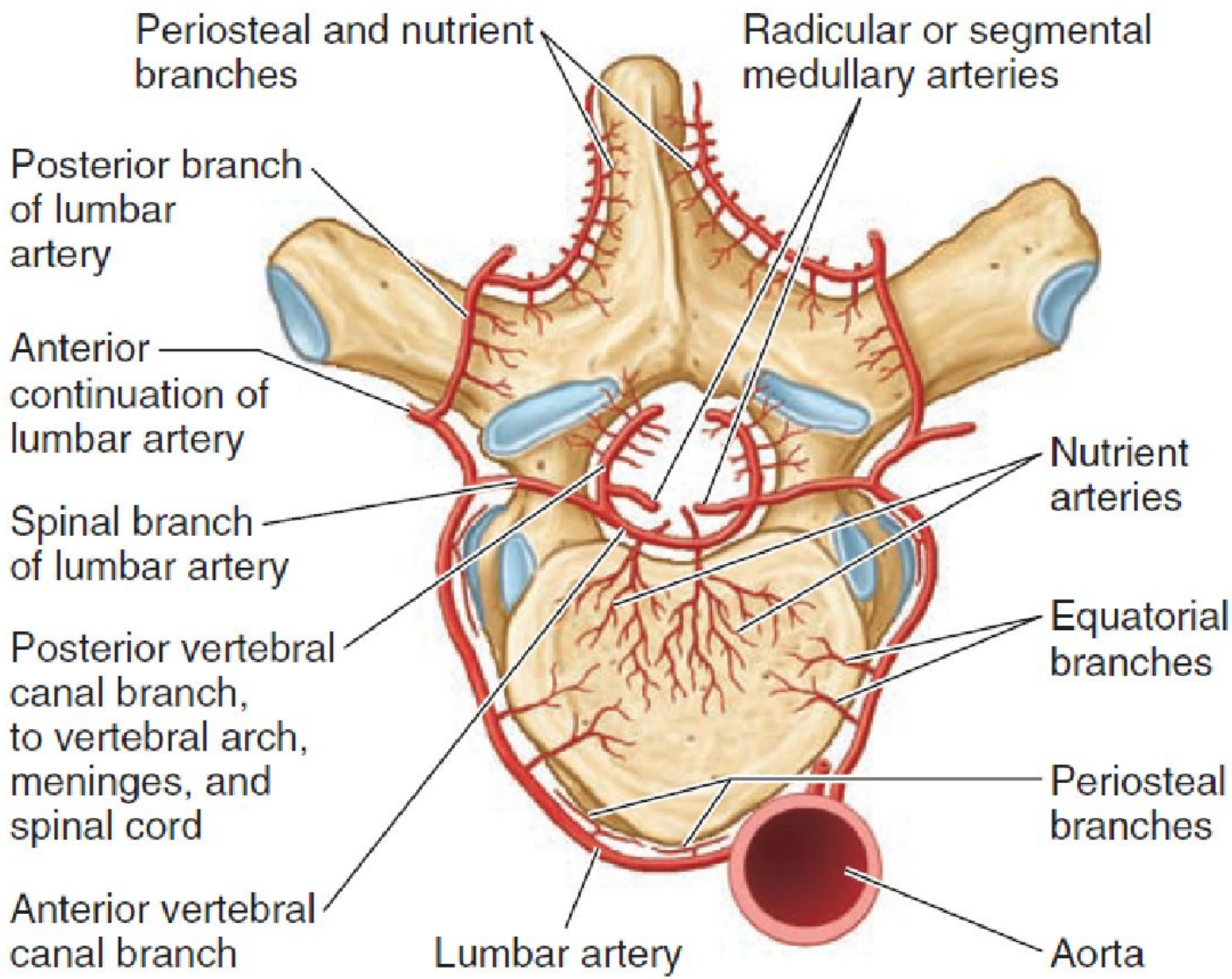
Periosteal and nutrient branches
Radicular or segmental medullary arteries
Posterior branch of lumbar artery
Anterior continuation of lumbar artery
Spinal branch of lumbar artery
Posterior vertebral canal branch, to vertebral arch, meninges, and spinal cord
Anterior vertebral canal branch
Lumbar artery
Nutrient arteries
Equatorial branches
Periosteal branches
Aorta

- ***Spinal veins*** form venous plexuses along the vertebral column both inside (***internal vertebral epidural venous plexus***) and outside (***external vertebral venous plexus***) the vertebral canal.
- The large, tortuous ***basivertebral veins*** form within the vertebral bodies and emerge from foramina on the surfaces of the vertebral bodies (mostly the posterior aspect) and drain into the external and especially the internal vertebral venous plexuses.
- The ***intervertebral veins*** receive veins from the spinal cord and vertebral venous plexuses as they accompany the spinal nerves through the IV foramina to drain into the vertebral veins of the neck and segmental veins of the trunk.

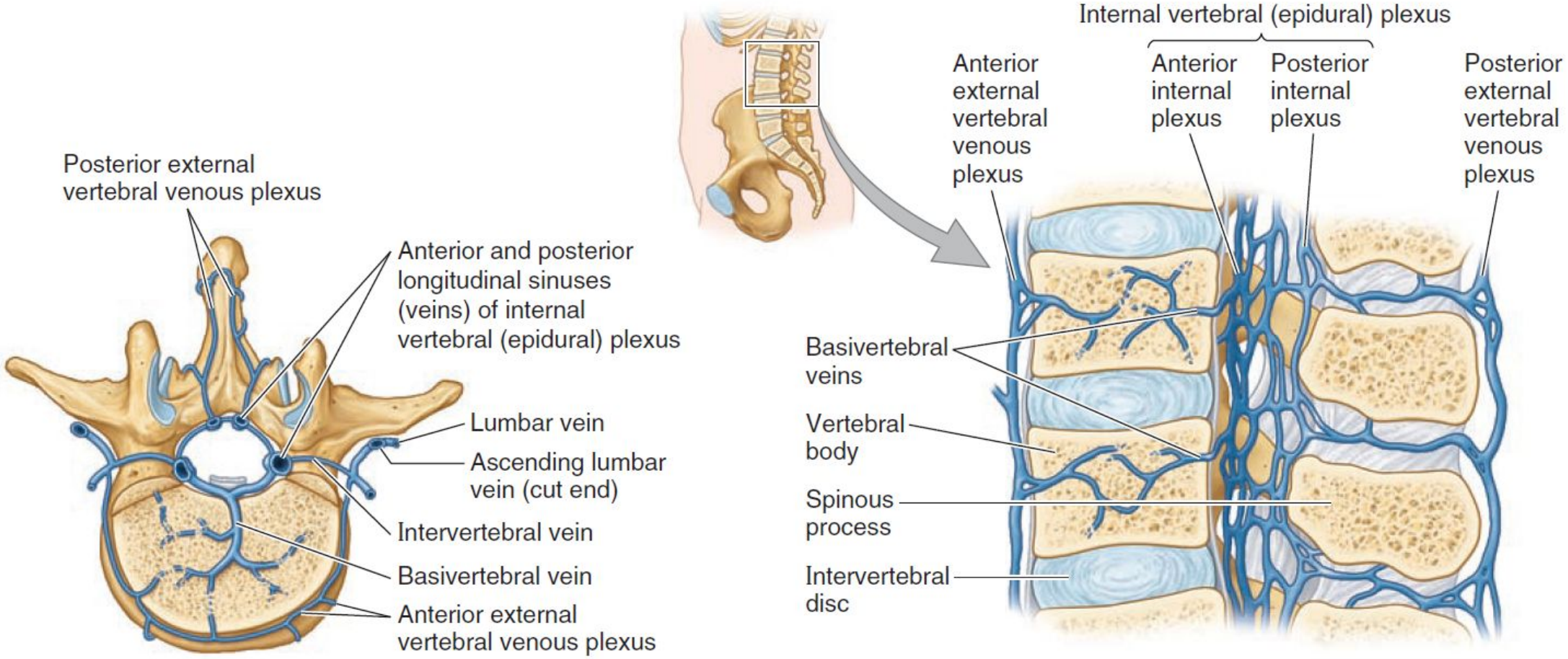

(A) Superior view

(B) Median section

Innervation of Vertebral Column

- Other than the zygapophysial joints (innervated by ***articular branches of the medial branches of the posterior rami***), the vertebral column is innervated by meningeal branches of the spinal nerves.
- ***Recurrent branches of the meningeal nerves*** run back through the IV foramen, but some branches remain outside the canal.
- The branches outside the canal supply the anuli fibrosi and anterior longitudinal ligament; recurrent branches supply the periosteum, ligamenta flava, anuli fibrosi posteriorly, posterior longitudinal ligament, spinal dura mater, and blood vessels within the vertebral canal.

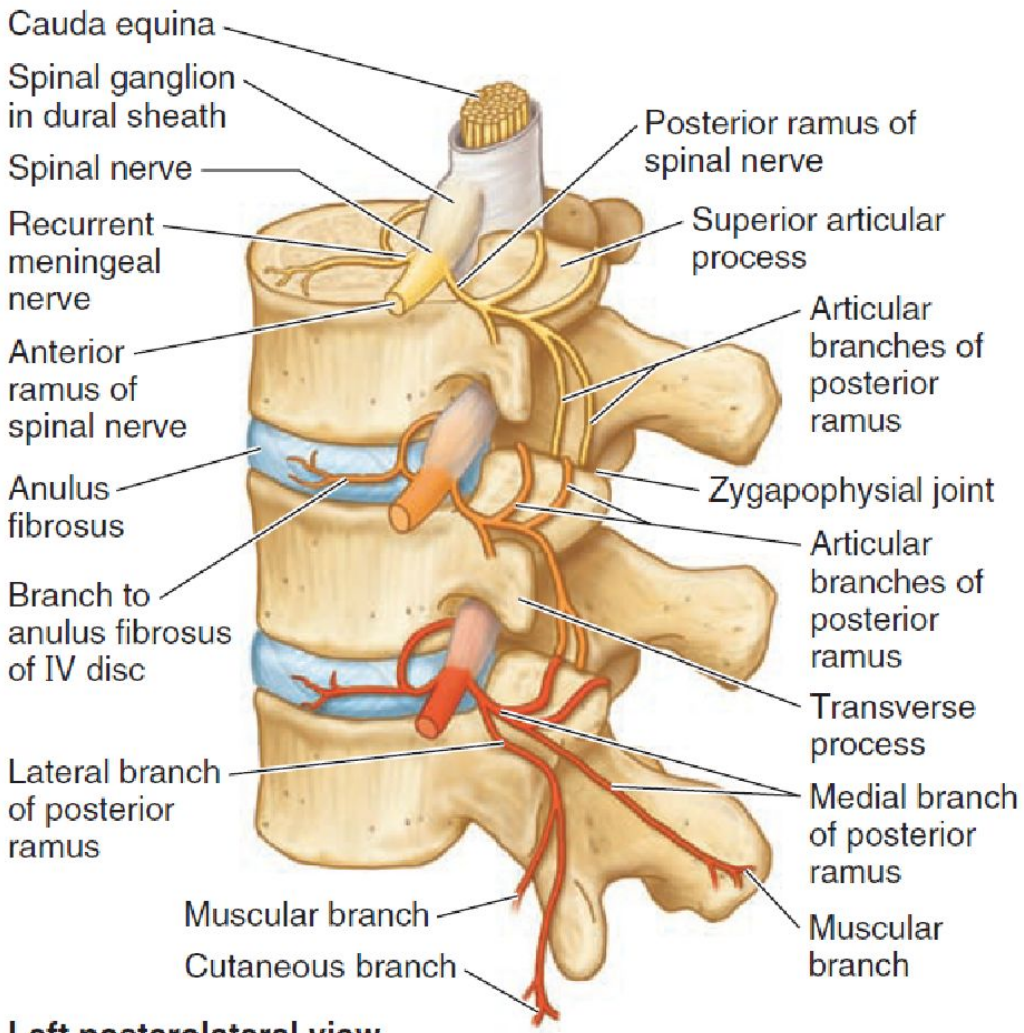

Left posterolateral view

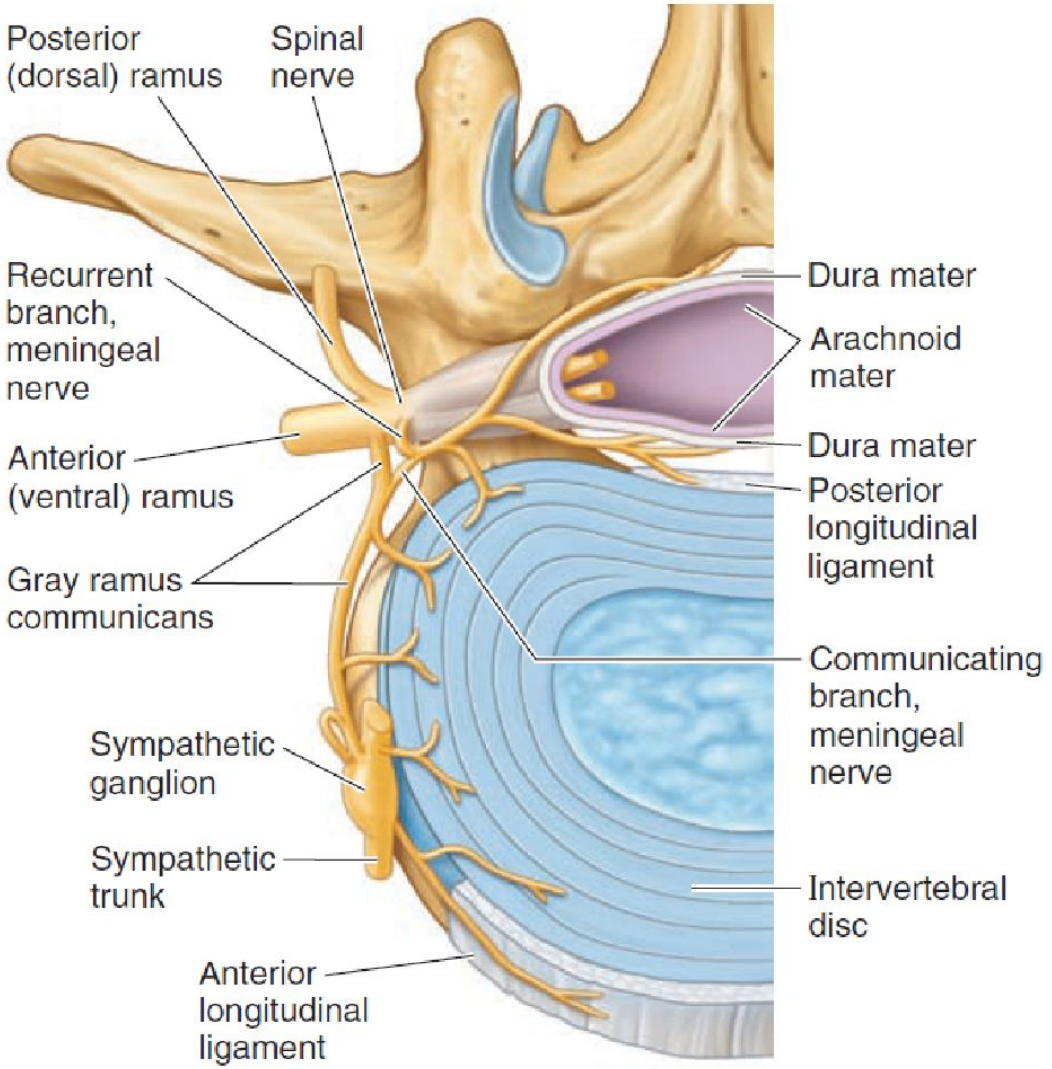

Superior view

The End

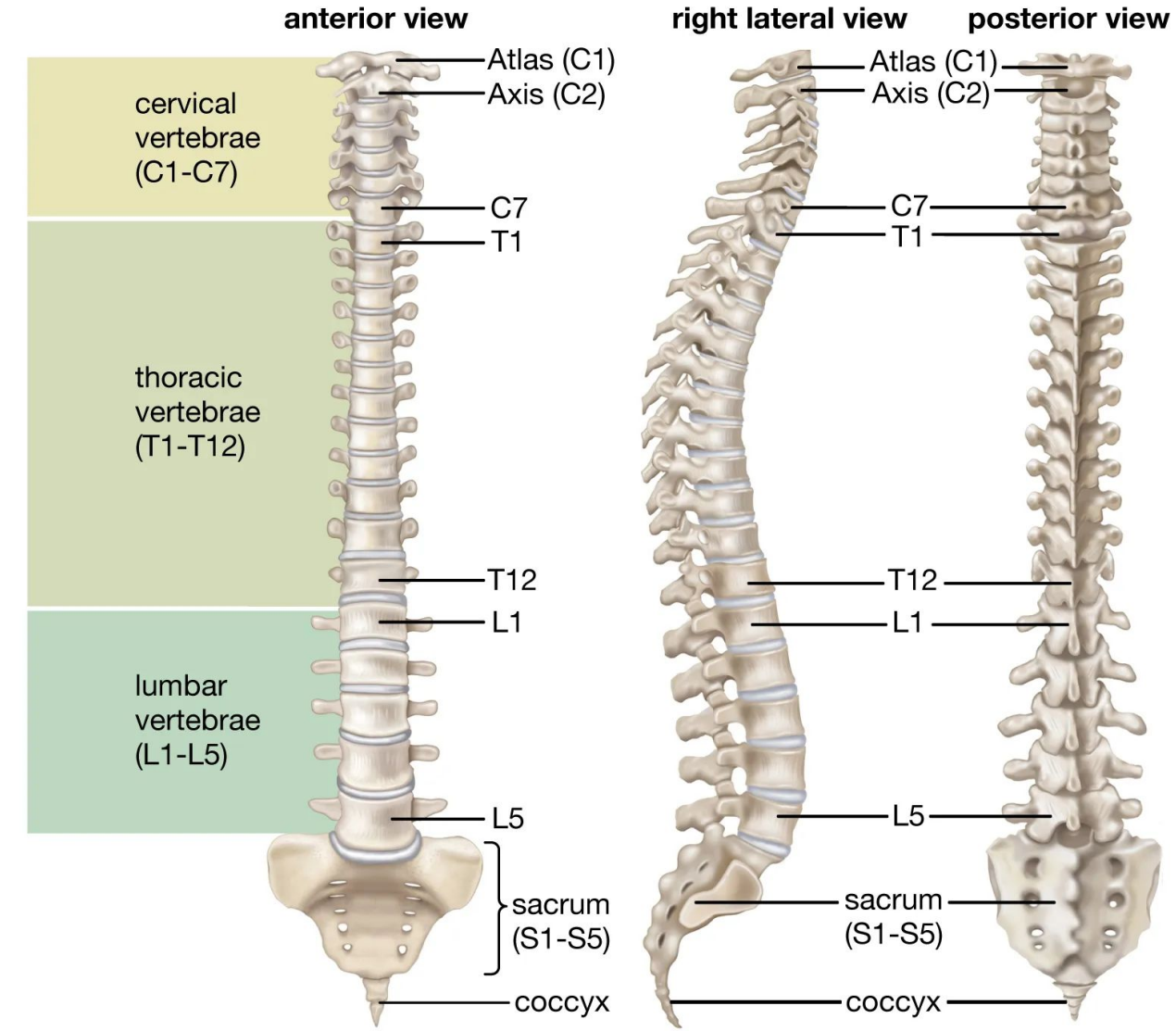

© Encyclopædia Britannica, Inc.